

ORIGINAL RESEARCH ARTICLE

Clinical effects of laparoscopic versus open radical prostatectomy in the treatment of early prostate cancer

DOI: 10.29063/ajrh2025/v29i2.12

Yi Guan, Changbin Tan, Hengcheng Zhu, Haoyong Li, Haitao Liu, Wei Hu, Huajie Song and Fei Xiao*

Department of Urology, Renmin Hospital of Wuhan University, Wuhan, Hubei 430200, China

*For Correspondence: Email: xiaofei19871031@163.com

Abstract

The objective of this study was to investigate the clinical effects of laparoscopy vs open radical prostatectomy in treating early prostate cancer. Eighty-six early prostate cancer patients accepted therapy in Renmin Hospital of Wuhan University from January 2020 to June 2022 were chosen to be the study participants. They were randomly divided into a control group (CG) and a study group (SG). The CG received open radical prostatectomy. By contrast, the SG underwent laparoscopic radical prostatectomy. Relative to the CG, the SG presented longer surgery time, shorter hospital stay, drainage tube indwelling time, urinary catheter indwelling time and gastrointestinal function recovery time, less intraoperative blood loss, lower occurrence of postoperative intestinal obstruction, and lower occurrence of urinary incontinence after one week, one month and three months after surgery. The SG also had lower the postvoid residual urine, reduced international prostate symptom score, and elevated maximum urinary flow rate at six months after surgery. We conclude that laparoscopic surgery for early prostate cancer is associated with clearer vision, less trauma, less intraoperative bleeding, faster postoperative recovery, and fewer complications as compared to open radical prostatectomy, and has more valuable for clinical outcomes. (*Afr J Reprod Health* 2025; 29 [2]:106-112).

Keywords: Early prostate cancer; laparoscopic radical prostatectomy; open radical prostatectomy; postoperative recovery

Résumé

L'objectif de cette étude était d'étudier les effets cliniques de la laparoscopie par rapport à la prostatectomie radicale ouverte dans le traitement du cancer précoce de la prostate. Quatre-vingt-six patients atteints d'un cancer précoce de la prostate ayant accepté un traitement à l'hôpital Renmin de l'Université de Wuhan de janvier 2020 à juin 2022 ont été choisis pour participer à l'étude. Ils ont été répartis au hasard en un groupe témoin (CG) et un groupe d'étude (SG). Le CG a subi une prostatectomie radicale ouverte. En revanche, le SG a subi une prostatectomie radicale laparoscopique. Par rapport au CG, le SG présentait une durée chirurgicale plus longue, un séjour à l'hôpital plus court, un temps de séjour dans le tube de drainage, un temps de séjour du cathéter urinaire et un temps de récupération de la fonction gastro-intestinale, moins de perte de sang peropératoire, une fréquence moindre d'obstruction intestinale postopératoire et une fréquence moindre d'incontinence urinaire après une semaine, un mois et plusieurs mois après la chirurgie. Le SG a également montré une diminution de l'urine résiduelle post-mictionnelle, une réduction du score international des symptômes de la prostate et un débit urinaire maximal élevé six mois après la chirurgie. Nous concluons que la chirurgie laparoscopique du cancer de la prostate précoce est associée à une vision plus claire, à moins de traumatismes, à moins de saignements peropératoires, à une récupération postopératoire plus rapide et à moins de complications par rapport à la prostatectomie radicale ouverte, et qu'elle a plus de valeur pour les résultats cliniques. (*Afr J Reprod Health* 2025; 29 [2]: 106-112).

Mots-clés: Cancer précoce de la prostate, prostatectomie radicale laparoscopique, prostatectomie radicale ouverte, récupération postopératoire

Introduction

Prostate cancer belongs to a type of the high incidence malignancies of the urinary system¹. Its incidence is related to age, diet structure, obesity, genetics, and other factors, which seriously influences the quality of life, along with physical and mental health of patients².

Recently, with the continuous improvement of people's health awareness along with various screening technologies, the detection percentage of early prostate cancer has increased significantly³. In the past, the main treatment method of early prostate cancer was transabdominal open radical prostatectomy, but it has the shortcomings of large surgical trauma along with many postoperative complications⁴. In addition, with the advancement of

endoscopic technology, laparoscopic technology has been extensively applied in surgery⁵. Laparoscopic radical prostatectomy (LRP) has emerged as an important method for treating early prostate cancer due to the strengths of less trauma, fewer postoperative complications, as well as rapid postoperative recovery of patients⁶. As reported previously, compared to open radical prostatectomy, LRP shows superior sexual outcomes at 1 year, improved urinary outcomes at 18 months, and comparable oncological outcomes at 36 months⁷. Besides, Ghavamian *et al.* suggested that LRP is well tolerated and provides short-term oncologic and functional results comparable to those of open radical prostatectomy⁸. Anastasiadis *et al.* pointed out that compared to open radical prostatectomy, the recovery of nocturnal continence seemed to occur earlier after the LRP⁹. Rassweiler *et al.* indicated that compared to open radical prostatectomy, LRP was technically demanding, with an initially longer operative time, higher incidence of rectal injuries and urinary leakage, but the overall outcome after 219 cases favored LRP¹⁰.

Based on the above information, this study compared the clinical outcomes in patients undergoing laparoscopic prostatectomy as compared to those with open radical prostatectomy in the treatment of early prostate cancer.

Methods

Eighty-six early prostate cancer patients accepted therapy in Renmin Hospital of Wuhan University from January 2020 to June 2022 were chosen. They were randomly divided into a control group (CG) and a study group (SG) based on different surgical methods, with 43 cases in each group. The patients in the CG were aged 34-77 years, with a mean, SD age of 55.34±4.56 years. The patients in the SG were aged 35-78 years, with a mean, SD age of 56.02±4.48 years. There was no significant difference in the sociodemographic characteristics between the two groups ($P>0.05$).

The inclusion criteria were: (1) early prostate cancer confirmed by pathology; (2) no distant lymph node metastasis identified; (3) no contraindications to

surgery; and (4) all patients willing to take part in the study.

The exclusion criteria: (1) patients who had distant metastasis. (2) patients who had poor physical condition unable to perform surgery; and (3) patients with other organ dysfunction.

Findings

Patients in the CG received open retropubic radical prostatectomy. After the completion of tracheal intubation and general anesthesia, the patient's position was adjusted to supine position, and the whole pelvis was elevated. A straight and median incision was made from the pubic symphysis to the umbilical cord. The peritoneum was pushed upward and the entire pelvic lymph node was dissected first. Then the exact position of the bladder neck was determined according to the catheter balloon, and a transverse incision was made on the anterior wall of the neck to avoid damage to the ureter. The bladder triangle was transected after ureteral catheterization on both sides, and the posterior wall of the broken end of the bladder was turned upwards after the bladder was severed, and the prostate was separated in the posterior direction after the entire seminal vesicle and ampulla of the vas deferens were fully exposed. The pelvic fascia invert in the lateral wall of the pelvic bone was cut 2 cm at the side of the prostate, and blunt separation was performed. The prostate was separated from the rectum when the anatomic plane behind the prostate was reached, and the prostate was lifted up. The prostate was further separated backward and laterally until it reached the apex of the prostate. A 2-0 catgut was used to suture the broken end of the back wall of the bladder, the new bladder neck was reduced to an index finger, the ureter was opened away from the new bladder neck, the puboprostatic ligament was severed, the deep dorsal vein was ligated, the urethra was cut and anastomosed with the new bladder neck, and then the three-cavity balloon catheter was inserted, and the drainage tube and catheter were indwelled.

Patients in the SG underwent laparoscopic prostatectomy (LRP). Patient abstained from food and water before operation, and all operations were

implemented utilizing intravenous general anaesthesia. After successful induction of anaesthesia, the patient was placed in the supine position with head high and feet low. A soft pad was used on the buttocks, the two legs were separated, and a monitor was placed between the legs. A small incision was accurately taken 1 cm below the umbilicus, effective puncture was performed, CO₂ was injected, pneumoperitoneum was completed, and trocar was placed in turn. After careful separation of the iliac vessels, the pelvic lymph nodes were cleaned. Along the blood vessels, the lymphatic tissue and fat between the blood vessels and the pelvic wall were completely removed from the bifurcation of the common iliac vessels. According to the seven-step method made by Montsouris¹¹, the prostate tissue was dissociated, the bladder neck was cut off, and the two lateral walls of the prostate were in a free state, and the tip of the prostate was separated. Finally, the bladder neck was reconstructed. Routine catheter indwelling, active fluid replacement, antibiotics were utilized to prevent infection along with effective analgesia and hemostasis.

Observed indicators

- (1) The operation time, intraoperative blood loss, hospital stay, drainage tube indwelling time, urinary catheter indwelling time and gastrointestinal function recovery time in both groups were recorded.
- (2) The postoperative complications such as urinary leakage, urethral stricture and intestinal obstruction were observed in the two groups.
- (3) The incidence of urinary incontinence within six months following surgery was compared in both groups.
- (4) At six months following operation, postvoid residual (PVR) was tested by B-mode ultrasound, and maximum urinary flow rate (Q_{max}) was tested by WIEST8000 urodynamic analyzer (WIEST, Germany).
- (5) The international prostate symptom score (IPSS) in both groups was evaluated six months following operation.
- (6) The recurrence rate at one year after operation was compared in both groups.

Statistical analysis

SPSS 18.0 software was implemented for data analysis and processing. Measurement data exhibited as mean ± standard deviation were compared by means of t test between 2 groups. Count data exhibited as percentage were compared using χ^2 test between 2 groups. $P < 0.05$ meant the difference was significant.

Ethical consideration

Our study was approved by the Ethics Committee of Renmin Hospital of Wuhan University.

Results

Operation time, intraoperative blood loss, hospital stay, drainage tube indwelling time, urinary catheter indwelling time and gastrointestinal function recovery time in 2 groups

Relative to the CG, the SG had longer operation time, and shorter hospital stay, drainage tube indwelling time, urinary catheter indwelling time, and gastrointestinal function recovery time along with less intraoperative blood loss ($P < 0.05$, Figure 1).

Postoperative complications in the two groups

As shown in Table 1, the occurrence of postoperative intestinal obstruction in the SG was lower as compared to the CG ($P < 0.05$). However, there was no difference in the occurrence of urinary leakage and urethral stricture between both groups ($P > 0.05$).

Incidence of postoperative urinary incontinence in both groups

At one week, one month, and three months after surgery, the occurrence of urinary incontinence in the SG was lower than in the CG ($P < 0.05$). However, at six months following surgery, no difference was found in the occurrence of urinary incontinence between both groups ($P > 0.05$).

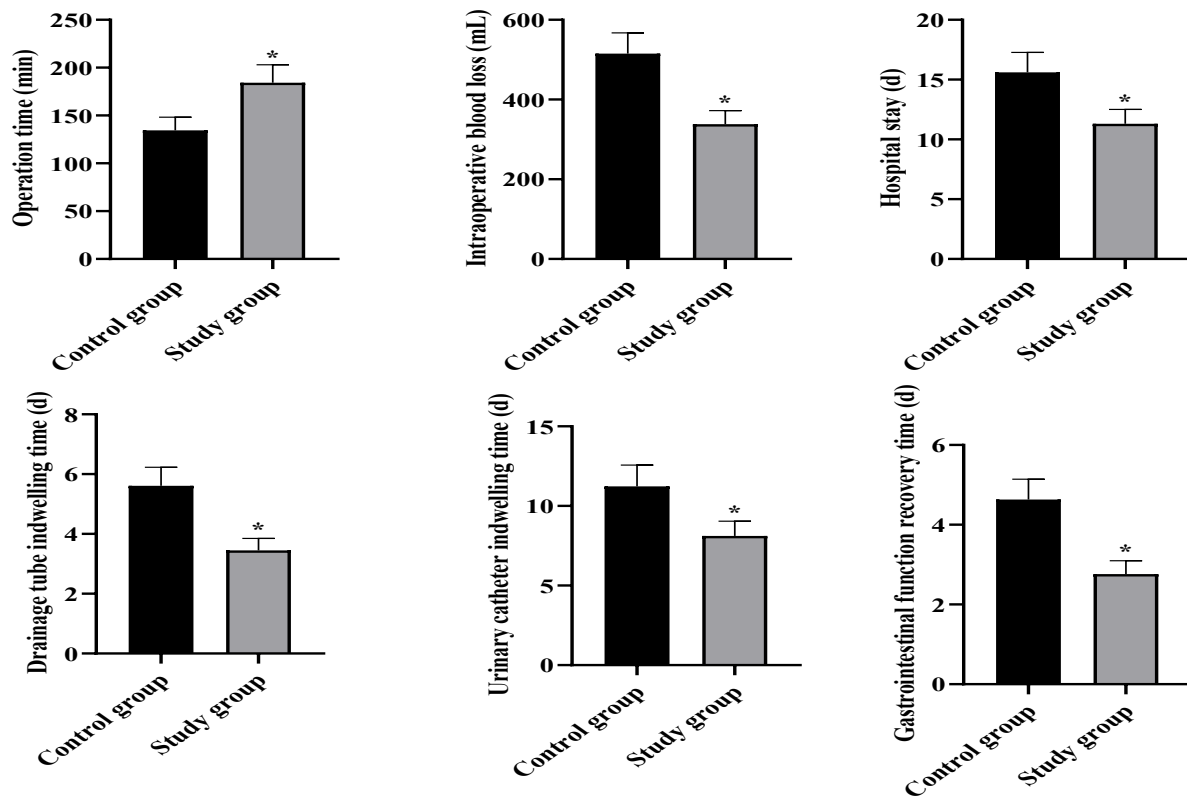


Figure 1: Operation time, intraoperative blood loss, hospital stay, drainage tube indwelling time, urinary catheter indwelling time and gastrointestinal function recovery time in 2 groups. *P<0.05

Table 1: Postoperative complications in both groups

Groups	n	Intestinal obstruction	Urinary leakage	Urethral stricture
Control group	43	9 (20.93%)	5 (11.63%)	6 (13.95%)
Study group	43	2 (4.65%)	4 (9.30%)	5 (11.63%)
χ^2 value		5.11	0.12	0.10
P value		<0.05	>0.05	>0.05

Table 2: Incidence of postoperative urinary incontinence in both groups

Groups	n	1 week after surgery	1 month after surgery	3 months after surgery	6 months after surgery
Control group	43	9 (20.93%)	7 (16.28%)	6 (13.95%)	1 (2.33%)
Study group	43	1 (2.33%)	1 (2.33%)	0 (0.00%)	0 (0.00%)
χ^2 value		7.24	4.96	6.45	1.01
P value		<0.05	<0.05	<0.05	>0.05

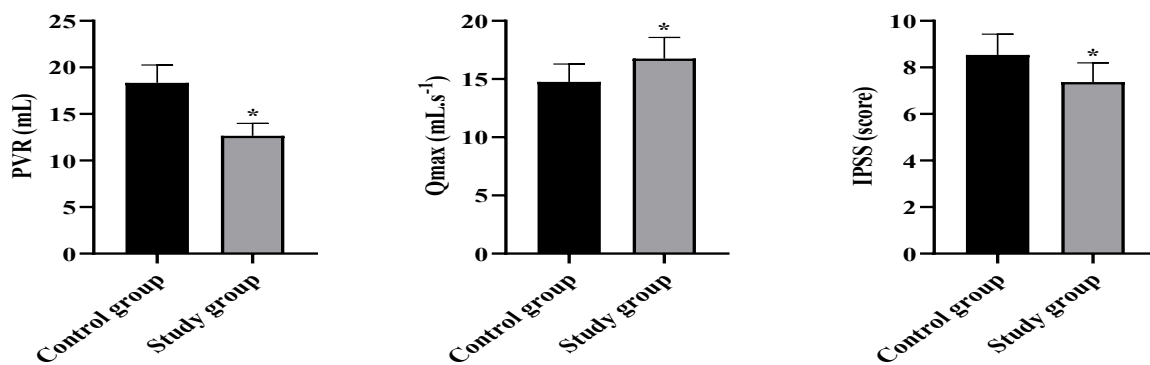


Figure 2: PVR, Qmax and IPSS scores at 6 months following operation in both groups. *P<0.05.

Table 3: Postoperative follow-up in both groups

Groups	n	Recurrence rate at 1 year after surgery
Control group	43	4 (9.30%)
Study group	43	3 (6.98%)
χ^2 value		0.16
P value		>0.05

Postvoid residual (PVR), maximum urinary flow rate (Qmax) and international prostate symptom score (IPSS) scores at 6 months following surgery in both groups

The results were presented in Figure 2. At 6 months following operation, compared with the CG, the PVR was decreased, IPSS score was declined while Qmax was elevated in the SG (P<0.05).

Postoperative follow-up in both groups

As shown in Table 3 that, at 1 year after operation, no difference was observed in recurrence rate between the two groups (P>0.05).

Discussion

Prostate cancer is one of the most frequent malignant tumors in the clinical urinary system¹². Radical prostatectomy is the major approach for early prostate cancer¹³, and endocrine therapy, chemotherapy and radiotherapy used in the treatment of advanced prostate cancer¹⁴. Recently,

with the changes in diet, the increased frequency of health examinations and the wider application of serum prostate-specific antigen test in clinical practice, the rate of diagnosis of early prostate cancer has increased¹⁵.

Radical prostatectomy is the major approach for treating early prostate cancer. These include open radical prostatectomy, laparoscopic radical prostatectomy (LRP), robotic-assisted LRP, as well as brachytherapy with particle implantation¹⁶. Open surgery is more traumatic, patients recover slowly after surgery, and there are more complications¹⁷. Robotic LRP is difficult and is less extensively used in clinical practice because of its high cost as well as low popularity^{18,19}. Recently, with the development of laparoscopic technology along with its popularization in hospitals, more LRPs are being carried out²⁰. Evidence from the literature indicates that LRP can significantly improve the treatment effect, reduce complications, and facilitate the rapid recovery of patients after surgery²¹.

The results of this study indicate that compared to the CG, the laparoscopic surgery group had longer operation time, shorter hospital stay, shorter drainage tube indwelling time, shorter urinary catheter indwelling time, shorter gastrointestinal function recovery time, as well as less intraoperative blood loss. The prostate is located deep in the pelvic cavity, and the Asian pelvis is relatively small, so the surgical operation space is small. In addition, the prostate is surrounded by blood vessels, nerves and other tissues, laparoscopic surgery is relatively

complex, and the operation time is relatively long. Laparoscopic surgery has high technical needs for instruments and surgeons. With the improvement of instruments and surgeons, the time of laparoscopic surgery will be gradually shortened. Besides, laparoscopic surgery through the monitor, the details can be displayed on the screen, the anatomical structure is more obvious and clear, and the surgical operation can be more accurate, fine and precise. It can effectively reduce the damage to peripheral nerves and blood vessels, reduce the amount of intraoperative blood loss and complications such as intestinal adhesion, intestinal obstruction and urinary incontinence. The outcomes of this research showed that at 6 months after operation, the SG had reduced postvoid residual (PVR), reduced international prostate symptom score (IPSS) score, and increased maximum urinary flow rate (Qmax) compared with the CG. This may be because laparoscopic operation is delicate, which can accurately handle important structures in the deep pelvic floor, better preservation of the bladder neck, less intraoperative traction, less damage to the bladder detrusor and urethral sphincter, and less stimulation of the urinary tract. Additionally, no difference was discovered in the recurrence rate between 2 groups 1 year after operation, indicating that laparoscopic surgery has a similar effect on tumor control compared with open surgery in early prostate cancer.

Study strengths and limitations

The diversity of outcome measures and one-year follow-up were the strengths of this study. The limited sample size is a limitation as well as all patients were from the same hospital. This study can provide a reliable choice for the operation of early prostate cancer.

Conclusion

Laparoscopic surgery for early prostate cancer harbors the strengths of clear vision, less trauma and intraoperative bleeding, faster postoperative recovery, as well as fewer complications, which is valuable for clinical promotion.

Acknowledgements

None

Contribution of authors

Yi Guan and Changbin Tan: conceived and designed the study. Hengcheng Zhu and Haoyong Li: collected and analysed the data. Haitao Liu, Wei Hu, Huajie Song and Fei Xiao: prepared the manuscript. All authors mentioned in the article approved the manuscript.

References

1. Wang G, Zhao D, Spring DJ and DePino RA. Genetics and biology of prostate cancer. *Genes Dev.* 2018; 32(17-18):1105-1140.
2. Schatten H. Brief Overview of Prostate Cancer Statistics, Grading, Diagnosis and Treatment Strategies. *Adv Exp Med Biol.* 2018; 1095:1-14.
3. Wilt TJ, Ullman KE, Linskens EJ, MacDonald R, Brasure M, Ester E, Nelson VA, Saha J, Sultan S and Dahm P. Therapies for Clinically Localized Prostate Cancer: A Comparative Effectiveness Review. *J Urol.* 2021; 205(4):967-976.
4. Ilic D, Evans SM, Allan CA, Jung JH, Murphy D and Frydenberg M. Laparoscopic and robotic-assisted versus open radical prostatectomy for the treatment of localised prostate cancer. *Cochrane Database Syst Rev.* 2017; 9(9):Cd009625.
5. Toohar R, Swindle P, Woo H, Miller J and Maddern G. Laparoscopic radical prostatectomy for localized prostate cancer: a systematic review of comparative studies. *J Urol.* 2006; 175(6):2011-7.
6. Schulam PG and Link RE. Laparoscopic radical prostatectomy. *World J Urol.* 2000; 18(4):278-82.
7. Nahas WC, Rodrigues GJ, Rodrigues Gonçalves FA, Sawczyn GV, Barros GG, Cardili L, Guglielmetti GB, Fazoli AJC, Cordeiro MD, Cassão VDA, Chade DC, Neves De Oliveira LC, Murta CB, Pontes Júnior J, Trindade EM, Bastos DA, Sarkis AS, Mitre AI, Trinh QD and Coelho RF. Perioperative, Oncological, and Functional Outcomes Between Robot-Assisted Laparoscopic Prostatectomy and Open Radical Retropubic Prostatectomy: A Randomized Clinical Trial. *J Urol.* 2024; 212(1):32-40.
8. Ghavamian R, Knoll A, Boczeko J and Melman A. Comparison of operative and functional outcomes of laparoscopic radical prostatectomy and radical retropubic prostatectomy: single surgeon experience. *Urology.* 2006; 67(6):1241-6.
9. Anastasiadis AG, Salomon L, Katz R, Hoznek A, Chopin D and Abbou CC. Radical retropubic versus laparoscopic

- prostatectomy: a prospective comparison of functional outcome. *Urology*. 2003; 62(2):292-7.
10. Rassweiler J, Seemann O, Schulze M, Teber D, Hatzinger M and Frede T. Laparoscopic versus open radical prostatectomy: a comparative study at a single institution. *J Urol*. 2003; 169(5):1689-93.
 11. Guillonneau B and Vallancien G. Laparoscopic radical prostatectomy: the Montsouris technique. *J Urol*. 2000; 163(6):1643-9.
 12. Sebesta EM and Anderson CB. The Surgical Management of Prostate Cancer. *Semin Oncol*. 2017; 44(5):347-357.
 13. Costello AJ. Considering the role of radical prostatectomy in 21st century prostate cancer care. *Nat Rev Urol*. 2020; 17(3):177-188.
 14. Cheng K, Wang Y, Chen Y, Zhu J, Qi X, Wang Y, Zou Y, Lu Q and Li Z. Multisite Radiotherapy Combined With Tislelizumab for Metastatic Castration-Resistant Prostate Cancer With Second-Line and Above Therapy Failure: Study Protocol for an Open-Label, Single-Arm, Phase Ib/II Study. *Front Oncol*. 2022; 12:888707.
 15. Fujita K, Hatano K, Tomiyama E, Hayashi Y, Matsushita M, Tsuchiya M, Yoshikawa T, Date M, Miyoshi E and Nonomura N. Serum core-type fucosylated prostate-specific antigen index for the detection of high-risk prostate cancer. *Int J Cancer*. 2021; 148(12):3111-3118.
 16. Gandaglia G, Montorsi F, Karakiewicz PI and Sun M. Robot-assisted radical prostatectomy in prostate cancer. *Future Oncol*. 2015; 11(20):2767-73.
 17. Porcaro AB, Tafuri A, Rizzetto R, Amigoni N, Sebben M, Shakir A, Odorizzi K, Gozzo A, Gallina S, Bianchi A, Ornaghi PI, Antonioli SZ, Locola V, Brunelli M, Migliorini F, Cerruto MA, Siracusano S, Artibani W and Antonelli A. Predictors of complications occurring after open and robot-assisted prostate cancer surgery: a retrospective evaluation of 1062 consecutive patients treated in a tertiary referral high volume center. *J Robot Surg*. 2022; 16(1):45-52.
 18. Basiri A, de la Rosette JJ, Tabatabaei S, Woo HH, Laguna MP and Shemshaki H. Comparison of retropubic, laparoscopic and robotic radical prostatectomy: who is the winner? *World J Urol*. 2018; 36(4):609-621.
 19. Gettman MT and Blute ML. Critical comparison of laparoscopic, robotic, and open radical prostatectomy: techniques, outcomes, and cost. *Curr Urol Rep*. 2006; 7(3):193-9.
 20. Bove P, Asimakopoulos AD, Kim FJ and Vespasiani G. Laparoscopic radical prostatectomy: a review. *Int Braz J Urol*. 2009; 35(2):125-37; discussion 137-9.
 21. Stolzenburg JU, Holze S, Arthanareeswaran VK, Neuhaus P, Do HM, Haney CM, Dietel A, Truss MC, Stützel KD, Teber D, Hohenfellner M, Rabenalt R, Albers P and Mende M. Robotic-assisted Versus Laparoscopic Radical Prostatectomy: 12-month Outcomes of the Multicentre Randomised Controlled LAP-01 Trial. *Eur Urol Focus*. 2022; 8(6):1583-1590.