

## ORIGINAL RESEARCH ARTICLE

# Surgery for giant ovarian cysts in Guyana using single-port laparoscopy: a retrospective case series analysis

DOI: 10.29063/ajrh2024/v28i12.12

Natasha France<sup>1</sup>, Radha Sookraj<sup>1</sup>, Sabrina Gittens<sup>1</sup> and Yuan Jiang<sup>2\*</sup>

Department of Obstetrics and Gynecology, Georgetown Public Hospital Corporation, Georgetown, Guyana<sup>1</sup>;  
Department of Obstetrics and Gynecology, Nanjing Drum Tower Hospital, Affiliated Hospital of Nanjing University Medical School, Nanjing, China<sup>2</sup>

\*For Correspondence: Email: jingzhanshi80441@163.com; jsource80@163.com

## Abstract

Giant ovarian cysts (GOCs) have become less common in developed countries due to routine health screenings, but they remain prevalent in economically underdeveloped regions. Treatment options for GOCs depend on factors such as age, cyst characteristics, and pregnancy status. Minimally invasive single-port laparoscopic surgery has largely replaced traditional open surgery due to its aesthetic advantages and effectiveness. In this case series, six patients with giant ovarian cysts, including two pregnant women, underwent single-port laparoscopic surgery. The procedure was aimed to reduce scarring, ensure safety, and preserve fertility. Strict criteria were used to rule out malignancy and assess suitability for the minimally invasive approach. Five patients had successful surgeries with positive cosmetic outcomes, while one required conversion to a mini-laparotomy due to technical difficulties. Postoperative recovery was smooth, with patients expressing satisfaction with the aesthetic results. This study demonstrates that single-port laparoscopic surgery is a safe and effective method for treating large ovarian cysts, combining the advantages of traditional laparoscopy with enhanced cosmetic results. The approach is particularly beneficial for younger and pregnant patients, with careful timing of surgery recommended to minimize pregnancy-related risks. (*Afr J Reprod Health 2024; 28 [12]: 108-115*).

**Keywords:** Giant ovarian cysts; Single-port laparoscopic surgery; Pregnancy; Minimally invasive surgery; Case series

## Résumé

Les kystes ovariens géants (GOC) sont devenus moins courants dans les pays développés en raison des examens médicaux de routine, mais ils restent répandus dans les régions économiquement sous-développées. Les options de traitement pour les GOC dépendent de facteurs tels que l'âge, les caractéristiques du kyste et l'état de grossesse. La chirurgie laparoscopique mini-invasive à un seul port a largement remplacé la chirurgie ouverte traditionnelle en raison de ses avantages esthétiques et de son efficacité. Dans cette série de cas, six patientes présentant des kystes ovariens géants, dont deux femmes enceintes, ont subi une chirurgie laparoscopique à un seul port. La procédure visait à réduire les cicatrices, à assurer la sécurité et à préserver la fertilité. Des critères stricts ont été utilisés pour exclure la malignité et évaluer l'adéquation de l'approche mini-invasive. Cinq patientes ont subi des interventions chirurgicales réussies avec des résultats esthétiques positifs, tandis qu'une a dû être convertie en mini-laparotomie en raison de difficultés techniques. La récupération postopératoire s'est déroulée sans problème, les patientes exprimant leur satisfaction quant aux résultats esthétiques. Cette étude démontre que la chirurgie laparoscopique à port unique est une méthode sûre et efficace pour traiter les gros kystes ovariens, combinant les avantages de la laparoscopie traditionnelle avec des résultats cosmétiques améliorés. L'approche est particulièrement bénéfique pour les patientes plus jeunes et enceintes, avec un timing minutieux de l'intervention chirurgicale recommandé pour minimiser les risques liés à la grossesse. (*Afr J Reprod Health 2024; 28 [12]: 108-115*).

**Mots-clés :** Kystes ovariens géants, Chirurgie laparoscopique à port unique, Grossesse, Chirurgie mini-invasive, Série de cas

## Introduction

Ovarian cysts are frequently encountered benign neoplasms in gynaecological practice, distinguished by their heterogeneous types and the variability in clinical presentations<sup>1</sup>. Specifically, giant ovarian cysts (GOCs) are defined as ovarian cysts whose

maximum diameter surpasses 10 centimeters<sup>2</sup>. Initially, these cysts may not manifest any discernible clinical symptoms and are often fortuitously identified during ultrasonographic evaluations. Nonetheless, with progressive growth, these cysts can enlarge significantly, extending inferiorly to the xiphoid process and eliciting a

spectrum of symptoms such as abdominal discomfort, distention, and effects stemming from the compression of adjacent organs, including increased urinary frequency, constipation, and emesis<sup>3-4</sup>.

The primary modality for treating ovarian cysts is surgical intervention, with laparoscopic surgery being widely utilised due to its minimally invasive nature<sup>5</sup>. Yet, the management of GOCs via laparoscopy has been historically challenged by the constrained intra-abdominal space and the potential hazard of cystic fluid leakage, which were traditionally viewed as deterrents for employing laparoscopic approaches<sup>6</sup>. Consequently, the surgical strategy for GOCs frequently necessitates a longitudinal laparotomy, which, by necessitating an incision exceeding 10 centimeters, not only heightens the risk for postoperative infections but also impacts negatively on the aesthetic outcomes, a concern particularly significant for young female patients.

In recent advancements within gynecological surgery, single-port laparoscopic surgery has emerged as an innovative technique, characterized by the utilization of a solitary incision of approximately 2 to 3 centimeters at the umbilical site to facilitate the entry of laparoscopic instruments<sup>7</sup>. This approach offers superior cosmetic outcomes, potentially achieving a scarless result, and facilitates the extraction of surgical specimens. The unique single-port device effectively prevents the spillage and contamination of cystic fluid from ovarian cysts during the surgical procedure<sup>8</sup>.

In our case series, we present six cases involving Giant ovarian cysts treated through single-port laparoscopic surgery at the Georgetown Public Hospital Corporation (GPHC) in Guyana. The principal aim of this case series is document the safety and efficacy of this technique for the treatment of giant ovarian cysts, aiming to provide experience and guidance for clinical practice.

## Methods

Between December 2022 and August 2023, Single-port laparoscopic surgery was performed on six patients diagnosed with giant ovarian cysts at the

Georgetown Public Hospital Corporation (GPHC) in Guyana. The case series received approval from the GPHC Research Committee.

Inclusion criteria: (1) All patients underwent abdominal ultrasound or CT scan before surgery, which confirmed the presence of a pelvic cystic mass with a diameter greater than 15 centimeters, and was suggestive of a benign nature. (2) Patients were informed about the surgical procedure and signed an informed consent form prior to surgery. (3) Preoperative examination showed no abnormalities at the umbilicus.

Exclusion criteria: (1) Preoperative suspicion of malignancy in the cyst; (2) Previous surgical history with preoperative imaging indicating pelvic adhesions.

Among the six patients, four non-pregnant patients underwent CT scans before surgery, while two pregnant patients had ultrasound examinations preoperatively. CT or ultrasound confirmed the presence of at least one giant cystic pelvic cyst measuring 15 centimeters or more, extending above the umbilical level, primarily cystic with no significant solid component. To minimize the impact of varying surgical experience on the outcomes, Every procedure was executed by the same gynaecologist (author JY), who possesses expertise in single-port laparoscopic surgery (Fig1.A-C).

Between December 2022 and August 2023, single-port laparoscopic surgery was performed on six patients diagnosed with giant ovarian cysts at Georgetown Public Hospital Corporation (GPHC) in Guyana. This case series received approval from the GPHC Research Committee.

### *Inclusion Criteria:*

- (1) All patients underwent an abdominal ultrasound or CT scan before surgery, confirming the presence of a pelvic cystic mass greater than 15 centimeters in diameter, suggestive of benign characteristics.
- (2) Patients were fully informed about the surgical procedure and provided written informed consent prior to surgery.
- (3) Preoperative examination indicated no abnormalities at the umbilicus.

### ***Exclusion Criteria:***

- (1) Preoperative suspicion of cyst malignancy.
- (2) Previous surgical history with preoperative imaging indicating pelvic adhesions.

Among the six patients, four non-pregnant patients received CT scans before surgery, while two pregnant patients had preoperative ultrasound examinations. The imaging confirmed the presence of at least one large cystic pelvic mass measuring 15 centimeters or more, extending above the umbilical level, primarily cystic with no significant solid component. To minimize the impact of variations in surgical experience on outcomes, all procedures were performed by the same gynecologist (author JY), an expert in single-port laparoscopic surgery (Figure 1. A-C).

### ***Ethical considerations***

This study was conducted in accordance with the ethical principles of the Declaration of Helsinki. Prior to surgery, all patients were fully informed of the surgical procedure, including potential risks and benefits, and each provided written informed consent to participate in the study. To maintain confidentiality, all patient information was handled anonymously. Identifiable information was removed or replaced in the data analysis and results reporting to protect patient privacy and ensure that no personally identifying details were disclosed.

Figure 1 Clinical data relating to six patients undergoing single-port laparoscopic surgery are shown in (Table 1). The data collected included age, cyst size, body mass index (BMI), history of gravidity, parity, volume of cystic fluid, histology, operation time, intraoperative blood loss and postoperative hospital stay. Patients were followed up 30 days postoperatively to assess their satisfaction with the umbilical scar. Based on the patients' subjective evaluation of the wound healing, it was categorized into grades 1-5, with higher scores indicating greater satisfaction.

### ***Surgical procedure***

General anesthesia was administered, and the patient's abdomen was sterilized with povidone-iodine until the gauze remained color-stable. Using

Allis clamps, the skin around the umbilicus was lifted, followed by a 2-3 cm vertical incision at the umbilical site. Access to the abdominal cavity was gained through sequential incisions of the skin, subcutaneous tissue, and peritoneum. Once intestinal adhesions were ruled out, a thyroid retractor expanded the incision. A single-port laparoscopic incision protector (HTKD medical, Beijing, China) was placed, securing the inner ring within the incision and positioning the external ring against the abdominal wall (Fig. 2A-B), before installing the single-port device. Laparoscopic examination confirmed the cyst's location below the incision and its smooth surface, suggesting a benign lesion. To mitigate the risks from sudden drops in abdominal pressure, cystic fluid was carefully aspirated using a syringe connected to a suction tube (Fig. 2C). In cystectomy cases, after fluid aspiration and cyst size reduction, the entire ovary was extracted through the incision for direct cystectomy before being returned to the abdominal cavity (Fig. 2D). For adnexectomy, the incision was sutured closed before returning the cyst to the abdominal cavity. After laparoscopic electrocoagulation and cutting the ovarian ligaments, the adnexa was removed, and the specimen extracted intact via the umbilical incision.

### ***Ethics approval and consent to participate***

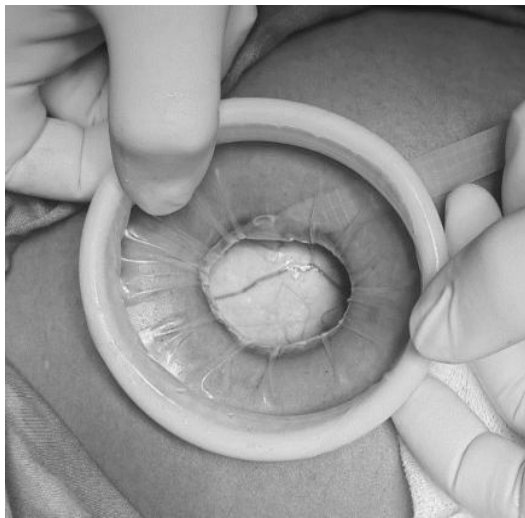
All cases performed in studies involving human participants were in accordance with the ethical standards of the institutional and national research committee and with the 1964 Helsinki Declaration and its later amendments. This study was approved by the Ethics Committee of Georgetown Public Hospital Corporation (date of approval: November 25 2022; reference number: GPHC20221125 , Guyana).

### **Results**

Our case series involved performing single-port laparoscopic surgery on six patients with giant ovarian cysts. Patient clinical data and surgical details are presented in (Table 1). The patients' average age was 41.8 years (range 23-83 years). The Body Mass Index (BMI) ranged from 16.8 to 31.2.

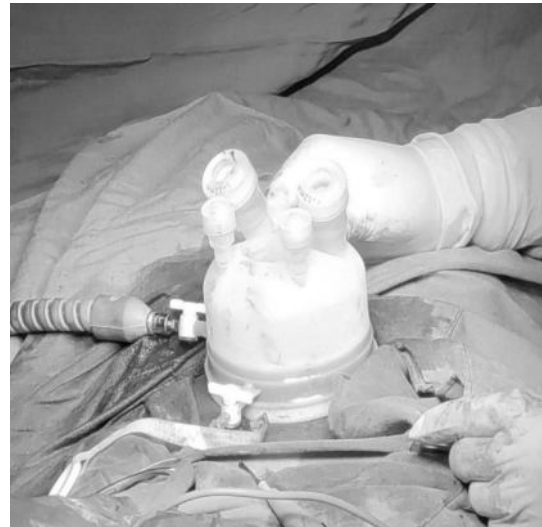**Table 1:** Clinical information of six patients undergoing single-port laparoscopic surgery

No	Age	Cyst size (cm*cm)	BMI	G	P	Fluid volume in cyst (ml)	Histology	Operative	Blood loss (ml)	Post-op.stay (day)	Satisfaction with abdominal scar
1	83	28x20	25.2	11	10	5800	Mucinous cystadenoma	100	100	4	4
2	31	25*17	20.2	1	0	3700	Mucinous cystadenoma	113	100	2	5
3	23	23*18	28.6	3	3	4200	Mature cystic teratoma	110	30	2	5
4	33	22*17	24.4	4	1	3300	Serous cystadenoma	45	10	2	5
5	49	29*17	29.2	2	1	4700	Mucinous cystadenoma	192	50	4	4
6	32	15*13	23.3	2	1	2800	Serous cystadenoma	50	50	4	4

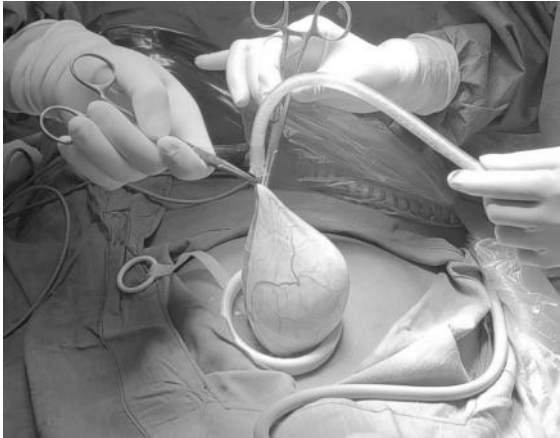
**Figure 2A:** The single-port laparoscopic incision protector was placed

The average gravidity and parity were 3.8 (range: 1-11) and 2.6 (range: 0-10), respectively, with no participants having prior abdominal surgeries. Two of these patients were pregnant with ovarian cysts, undergoing surgery at 13 and 16 weeks of gestation, respectively.

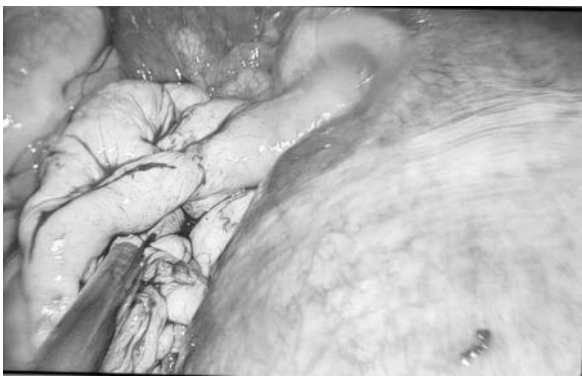
Five patients primarily experienced abdominal distention, and two of them also reported abdominal pain.

**Figure 2B:** Place the external part of the single-port device

One patient presented with a palpable abdominal mass, showing no other significant symptoms. Four non-pregnant patients underwent preoperative abdominal CT scans, and two pregnant patients received ultrasound examinations for their ovarian cysts. Imaging showed a median cyst diameter of 23.7 cm (range: 15-29 cm), with the largest cyst extending to the subxiphoid area, measuring 29 cm in diameter.



**Figure 2C:** The syringe connected to a suction tube



**Figure 2D:** The ovary of pregnancy patient after surgery

All four non-pregnant patients successfully underwent single-port laparoscopic surgery without requiring conversion to open surgery. Two patients had ipsilateral adnexectomy, and the other two had ipsilateral ovarian cystectomy. Patients 5 and 6 had ovarian cysts during pregnancy. At 12 weeks of gestation, Patient 5 experienced abdominal bloating, and an ultrasound showed a cyst on the left ovary. Surgery was delayed until 16 weeks of gestation to avoid stimulating the uterus and potentially causing a miscarriage, given the absence of abdominal pain. During the procedure, the left ovarian cyst was visualized below the umbilical incision. After aspirating the cystic fluid, cystectomy was performed by exteriorizing the left ovary through the umbilical incision. At 13 weeks of gestation, Patient 6 underwent single-port laparoscopic surgery for abdominal pain. After placing the single-port device,

the cyst was obscured by the uterus and was located posterior to it, as such it could not be adequately exposed. Consequently, the incision was extended 5 cm downwards from the umbilicus to facilitate open cystectomy. Both patients later had vaginal deliveries at 39 and 40 weeks of gestation, respectively.

Cosmetic suturing was employed for the umbilical incisions in patients undergoing single-port laparoscopy, with the average duration of surgery being 101.6 minutes (ranging from 45 to 192 minutes). The slow aspiration of cystic fluid using a fine needle prevented both the extravasation of cystic fluid and the occurrence of decompression syndrome associated with rapid fluid reduction. The average blood loss was 56 mL (ranging from 10 to 100 mL). The postoperative average hospital stay was 3 days (ranging from 2 to 4 days). All patients experienced favorable recoveries without any surgery-related complications.

Final pathology reports classified two cases as serous cystadenomas, three as mucinous cystadenomas, and one as a mature teratoma. Thirty days after surgery, all patients were satisfied with the appearance of their abdominal scars.

## Discussion

Ovarian cysts are common worldwide, affecting about 7% of women<sup>9</sup>. The occurrence of ovarian cysts during pregnancy ranges from 0.05% to 2.4%<sup>10</sup>. Patients may not show symptoms with small cysts, but larger cysts can cause noticeable discomfort<sup>10</sup>.

Giant ovarian cysts (GOCs), characterized as tumours larger than 10 cm in diameter, have become increasingly rare in developed countries due to the widespread availability of routine health screenings for women, including ultrasound examinations that can detect cysts when they are still small, allowing for early treatment<sup>11</sup>. In contrast, in less developed countries, limited access to routine health checks results in larger, more common giant ovarian cysts upon detection. Symptoms of giant ovarian cysts, such as abdominal bloating, pain, nausea, and vomiting, are often nonspecific<sup>12</sup>. In this case series, five of six patients sought medical attention for

abdominal bloating. Severe cases can lead to rare complications such as bowel obstruction and hydronephrosis.

Treatment strategies for ovarian cysts depend on the patient's age, cyst size and type, and pregnancy status<sup>13</sup>. For younger patients, ovarian cystectomy is often used to preserve healthy ovarian tissue and support future fertility<sup>14</sup>. In older patients, unilateral salpingo-oophorectomy might be performed to reduce the risk of complications. Before starting minimally invasive surgery, it's crucial to rule out ovarian cancer through detailed preoperative assessment, highlighting the need to differentiate between benign and malignant causes<sup>15</sup>.

Historically, laparotomy was the treatment modality of choice for managing giant ovarian cysts, primarily due to the necessity of accessing the sizable cystic structure. However, this approach often resulted in significant scarring, which could be of concern for young patients from an aesthetic standpoint<sup>16</sup>. Moreover, in pregnant patients undergoing laparotomy, the postoperative period poses risks such as impaired wound healing due to the continuous expansion of the uterus.

With the advent and refinement of minimally invasive surgical techniques, laparoscopic management of giant ovarian cysts has emerged as a viable alternative, circumventing the challenges associated with large incisions and potential cystic fluid leakage<sup>17</sup>. Single-port laparoscopy, leveraging the natural concavity of the umbilicus, offers an exceptional cosmetic outcome by concealing the surgical incision within the navel<sup>18</sup>. This technique facilitates enhanced operative visibility and minimizes the risk of intraoperative spillage of cyst contents through strategic incision placement and the protective mechanism of the single-port device's inner ring, which also reduces the likelihood of cellular dissemination. Additionally, the utilization of a slightly larger umbilical incision allows for the efficient removal of the excised specimen, potentially reducing operative duration<sup>19</sup>.

In our case series involving six patients, although one case necessitated conversion to a mini-laparotomy due to the inability to adequately expose the affected ovary post single-port device placement, postoperative wound healing was satisfactory across

the cohort, with all patients expressing contentment regarding the aesthetic outcome of their surgical scars. This underscores the feasibility and patient-centered benefits of single-port laparoscopic surgery in the treatment of large ovarian cysts, highlighting its role in minimizing cosmetic detriments while ensuring effective clinical management.

To minimize the effects of a sudden decrease in intra-abdominal pressure caused by the aspiration of cyst fluid, we utilized a fine needle attached to an aspirator to slowly remove the fluid within the cyst. This approach ensured that none of the patients experienced discomfort due to a rapid decline in abdominal pressure. For patients with concurrent pregnancy and large ovarian cysts, surgery is advised between the 14th and 18th weeks of gestation. This period is optimal because the placenta has already developed, reducing the uterus's sensitivity and thereby decreasing the risk of miscarriage following the procedure. Moreover, during this gestational phase, the uterus's enlargement aids in lifting the ovaries, simplifying the extraction of the cyst. In this study, of the two pregnant patients, one underwent single-port surgery at 13 weeks gestation due to symptoms of abdominal pain but required a mini-laparotomy due to the inability to adequately expose the ovary. The other, who was diagnosed with an ovarian cyst at 12 weeks without abdominal pain, waited until 16 weeks for the surgery. At that time, the ovarian condition was clearly visible through the single-port incision, allowing for the successful execution of the surgery.

Our investigation elucidates that single-port laparoscopic surgery does not exacerbate adverse prognosis in patients. Contrarily, the employment of a minimally invasive strategy coupled with exemplary aesthetic outcomes expedites the convalescence process and augments patient contentment levels. Despite the inherent merits associated with single-port laparoscopic procedures, their applicability is not universally extendable to all instances of voluminous ovarian cysts. An exhaustive evaluation of the patient's medical profile is imperative prior to undertaking surgery. The preoperative exclusion of malignancies is paramount. The constrained operative field and the proximal arrangement of surgical instruments

inherent to single-port laparoscopic surgery impose a heightened demand on the surgeon's dexterity due to the potential for instrument interference. It is incumbent upon the medical community to pursue further research aimed at augmenting the procedural safety and effectiveness of this surgical modality.

## Conclusion

Through meticulous patient selection, single-port laparoscopic surgery for the treatment of large ovarian cysts has been demonstrated to be safe and feasible. This surgical technique inherits all the advantages of traditional laparoscopic surgery, ensuring the highest level of safety during the procedure while significantly enhancing the cosmetic outcome. This aspect is particularly important for young patients and those who are pregnant, as it offers an effective treatment solution while also meeting the patients' expectations for aesthetic recovery.

## Consent for publication

Not applicable.

## Competing interests

The authors declare no competing interests.

## Funding

The author(s) declare that no financial support was received for the research, authorship, and/or publication of this article.

## Availability of data

The dataset used and analysed during the current study is available from the corresponding author on reasonable request.

## Acknowledgements

The authors gratefully acknowledge the faculty and staff of the department of obstetrics and Gynecology at GPHC, as well as the participating patients.

## Author contributions

NF, RS, and JY conceived of and designed the study. NF conducted the analysis and wrote the first draft of the manuscript, which was revised by JY. SG conducted the analysis and interpreted the results. All authors read, revised, and approved the final manuscript.

## References

1. Wheeler V, Umstead B and Chadwick C. Adnexal Masses: Diagnosis and Management. *Am Fam Physician*. 2023;108(6):580-7.
2. Katke RD. Giant Mucinous Cystadenocarcinoma of Ovary: A Case Report and Review of Literature. *J Midlife Health* (2016) 7(1):41-4.
3. Jiang L, Zhao X, Han Y, Liu K and Meng X. Giant Ovarian Cysts Treated by Single-Port Laparoscopic Surgery: A Case Series. *Front Oncol* (2021) 11:796330.
4. Kim HY, Cho MK, Bae EH, Kim SW and Ma SK. Hydronephrosis Caused by a Giant Ovarian Cyst. *Int Braz J Urol* (2016) 42(4):848-9.
5. Biggs WS and Marks ST. Diagnosis and Management of Adnexal Masses. *Am Fam Physician* (2016) 93(8):676-81.
6. Ng ZQ, Pradhan S and Wijesuriya R. Dilemma of the Giant Abdominal Cyst. *BMJ Case Rep* (2019) 12(1).
7. Han L, Wan Q, Chen Y and Zheng A. Single-Port Laparoscopic Surgery for Adnexal Mass Removal During Pregnancy: The Initial Experience of a Single Institute. *Front Med (Lausanne)* (2021) 8:800180.
8. Nakayama K, Yoshimura Y, Razia S, Yamashita H, Ishibashi T, Ishikawa M, Sasamori H, Sawada K, Kurose S, Sato S and Kyo S. Single-Port Laparoscopic Surgery for Ovarian Cystectomy: A Single-Center Analysis of 25 Cases. *Mol Clin Oncol* (2021) 15(2):160.
9. Farghaly SA. Current Diagnosis and Management of Ovarian Cysts. *Clin Exp Obstet Gynecol* (2014) 41(6):609-12.
10. McMinn E and Schwartz N. Adnexal Masses in Pregnancy. *Clin Obstet Gynecol* (2020) 63(2):392-404. Epub 2020/03/14.
11. Dubuisson J, Heersche S, Petignat P and Undurraga M. Laparoscopic Management of Giant Ovarian Cysts Using the Alexis Laparoscopic System®: A Case Series. *Front Surg* (2020) 7:24.
12. Sharen G, Chen H and Zhao H. Transumbilical Laparoendoscopic Single-Site Surgery with a Self-Made Port to Remove Giant Ovarian Cysts. *Asian J Surg* (2021) 44(8):1091-3.
13. Xiao J, Zhou J, Liang H, Liu F, Xu C and Liang L. Impact of Hemostatic Methods on Ovarian Reserve and Fertility in Laparoscopic Ovarian Cystectomy. *Exp Ther Med* (2019) 17(4):2689-93.
14. Canlorbe G, Chabbert-Buffet N and Uzan C. Fertility-

- Sparing Surgery for Ovarian Cancer. *J Clin Med* (2021) 10(18).
15. Albers CE, Ranjit E, Sapra A, Bhandari P and Wasey W. Clinician Beware, Giant Ovarian Cysts Are Elusive and Rare. *Cureus* (2020) 12(1):e6753.
  16. Ishikawa H and Shozu M. Modified Leak-Proof Puncture Technique for the Aspiration of Giant Ovarian Cysts by Instantly Mounting a Plastic Wrap and Gauze with Cyanoacrylates: A Retrospective Observational Study. *Front Surg* (2022) 9:948073.
  17. Sireesha MU, Chitra T, Subbaiah M and Nandeesh H. Effect of Laparoscopic Ovarian Cystectomy on Ovarian Reserve in Benign Ovarian Cysts. *J Hum Reprod Sci* (2021) 14(1):56-60.
  18. Jiang X, Zuo X and Zhu H. Laparoendoscopic Single-Site Technique Contrasted with Conventional Laparoscopy in Cystectomy for Benign Ovarian Cysts. *Curr Ther Res Clin Exp* (2023) 99:100713.
  19. Chong GO, Hong DG and Lee YS. Single-Port (Octoport) Assisted Extracorporeal Ovarian Cystectomy for the Treatment of Large Ovarian Cysts: Compare to Conventional Laparoscopy and Laparotomy. *J Minim Invasive Gynecol* (2015) 22(1):45-9.